

**PATIENT**

Stella Rail

**SPECIES**

Canine

**BREED**

Australian Shepherd

**SEX**

FS

**AGE**

14y

**WEIGHT**

73lbs

**INTERPRETED BY**

Maggie Machen  
Lamy, DVM, DACVIM  
(Cardiology)

**HOSPITAL NAME**

Sutherlin Veterinary  
Hospital

**REFERRING VET**

Dr. Herrera

**PRESENTING CLINICAL SIGNS**

History: Acute onset collapse, coughing mm slight lavender mm, crt 2 sec slight cardiomegally VHS 10.85 PVC on ECG; hypertensive 165/104/111, 165/91/116, 162/109/125 feeds duck and chick pea, lamb and pea diets  
Pertinent echo findings: CVD B1 (EL 3/4/22)

**ELECTROCARDIOGRAPHIC FINDINGS** \*Note: Single lead ECGs are evaluated as a rhythm strip. Morphology/MEA cannot be definitively commented on.

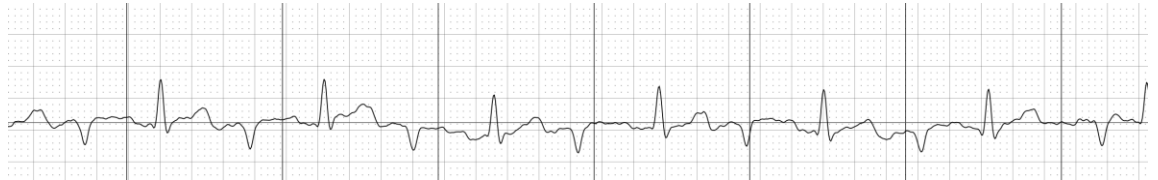
A single lead ECG is available; 50mm/s, 20mm/mV. Significant baseline artifact. The average heart rate is 120bpm (range 111-130bpm). The rhythm is sinus in origin, with a p for every QRS complex and vice versa. No obvious premature beats are identified; however, these are not entirely ruled out. No pauses or other dysrhythmias observed.  
ECG diagnosis: Normal sinus rhythm.

**INTERPRETATION OF THE FINDINGS & FURTHER RECOMMENDATIONS**

No obvious arrhythmias are identified on this ECG. Atypical negative deflections are seen between QRS complexes; however, they do not reset the sinus node and are suspected to be artifactual. Because of these however, premature beats are not entirely ruled out given the history.

If suspicion for premature beats persists, or certainly if the patient has further unexplained collapse episodes reassessing the ECG, referring to a facility with a 6 lead tracing, and/or a holter monitor may become indicated.

**IMAGES**



The information and recommendations provided are based on the images presented by the referring veterinarian. No evaluation can be communicated regarding pathology that was not visible in the image/video clips provided.

Thank you for this referral. If the clinical or image interpretation does not parallel your findings or if I can be of any further assistance please contact me.

Maggie Machen Lamy, DVM  
Diplomate of the American College of Veterinary Internal Medicine (Cardiology)  
info@sonopath.com

**INVOICE**

22956

**DATE**

3/4/22